

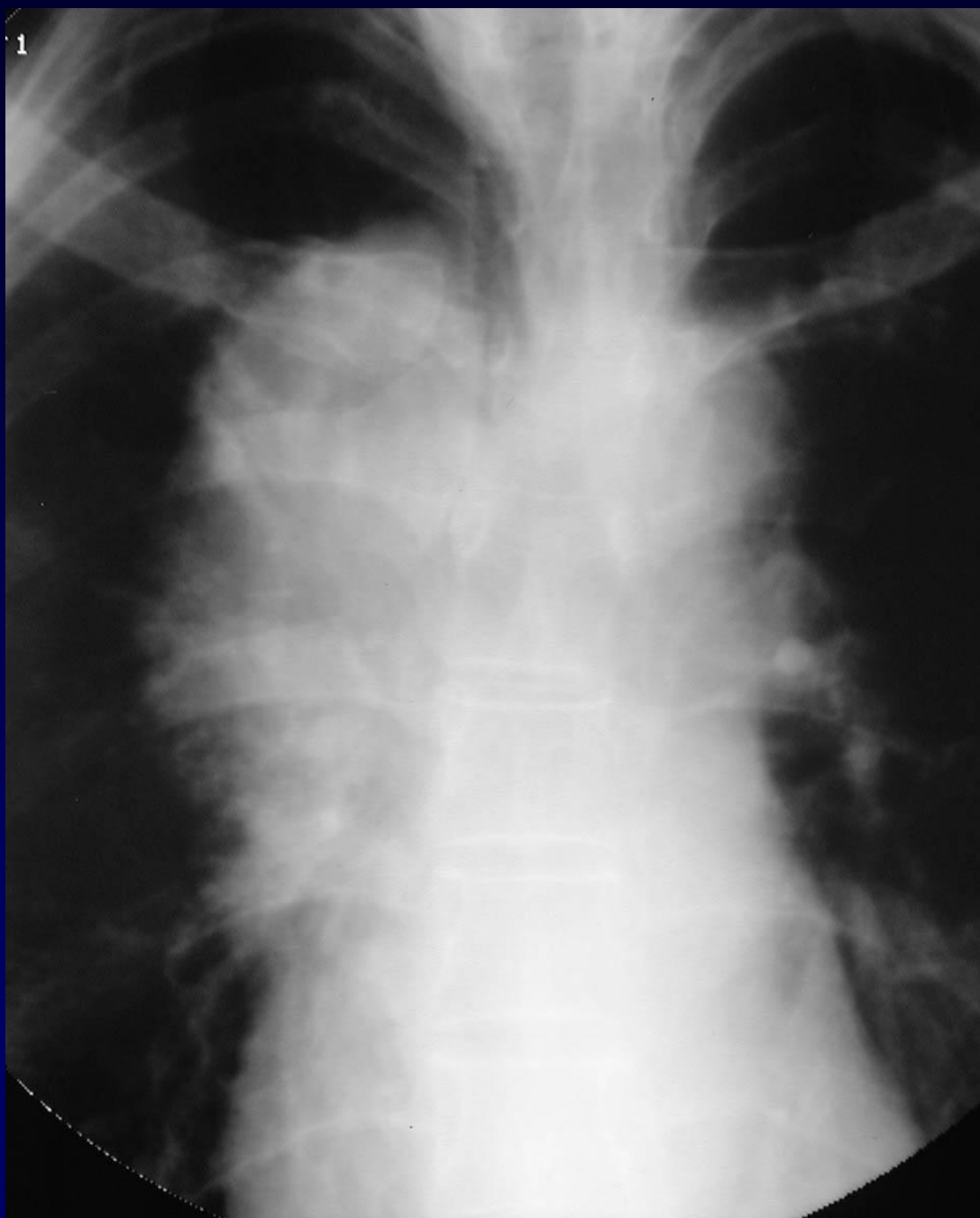

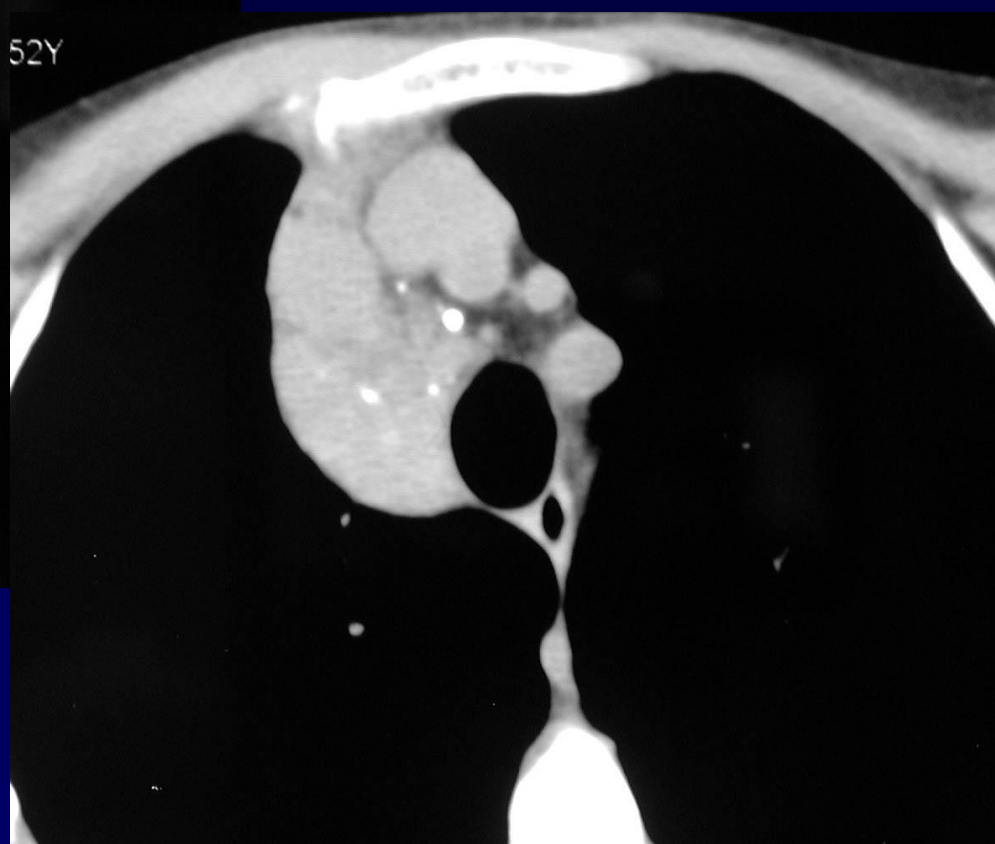
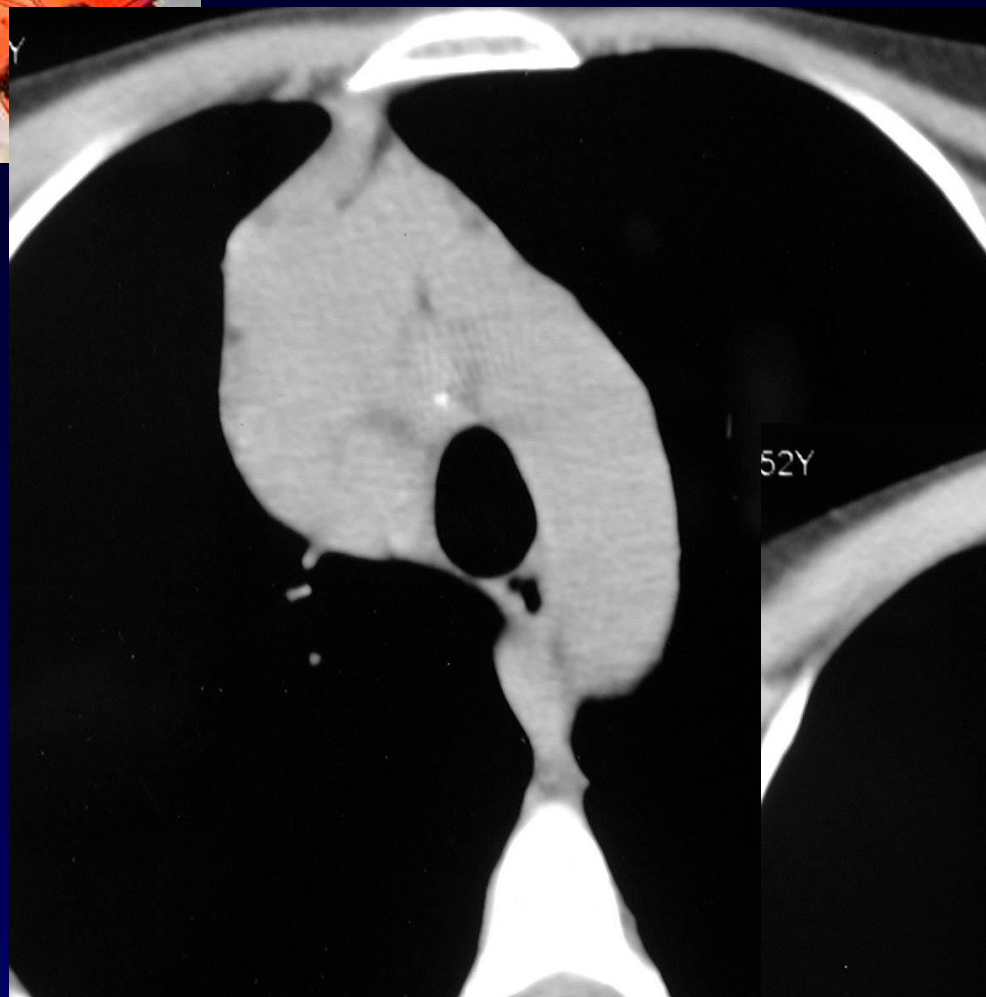

B GHAYE

Femme de 53 ans

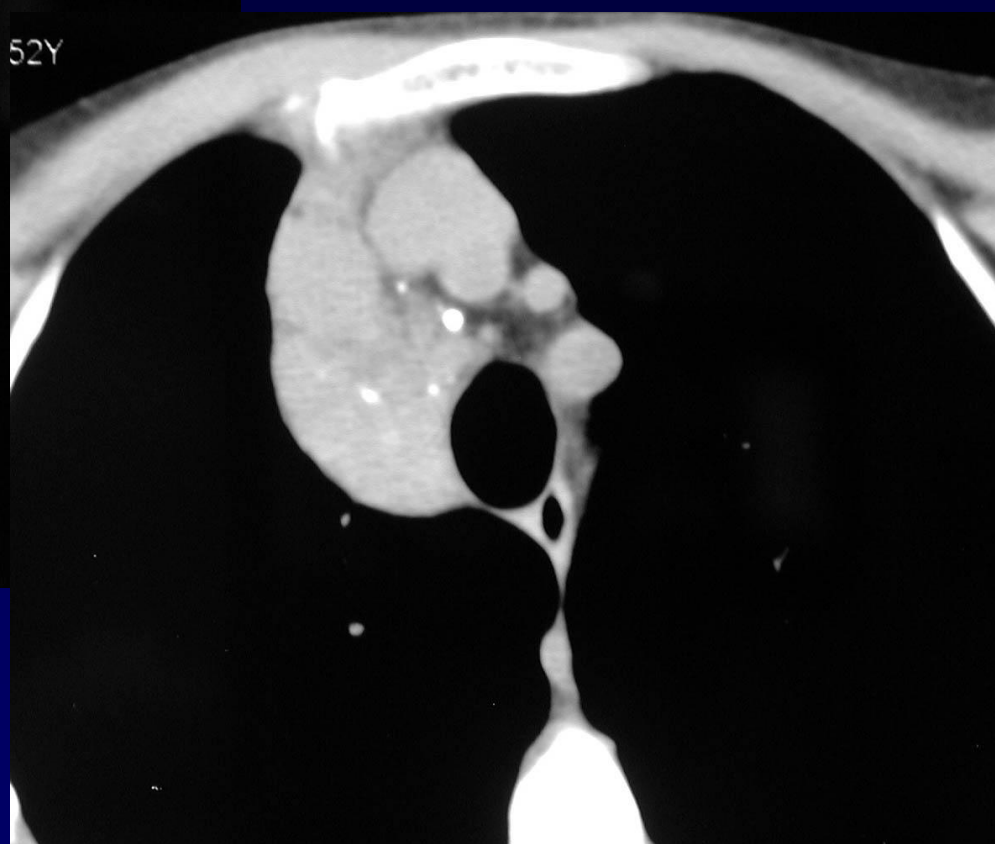
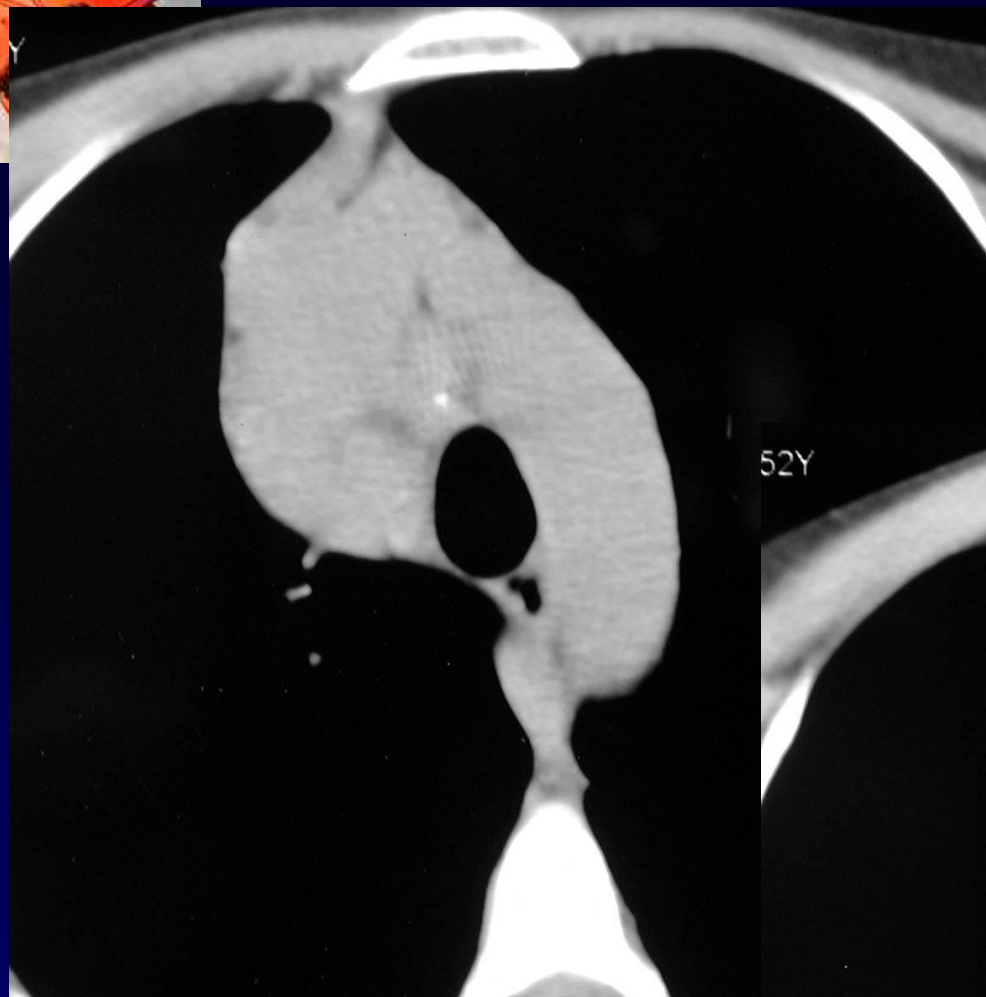
Antécédent traumatique

Actuellement asymptomatique

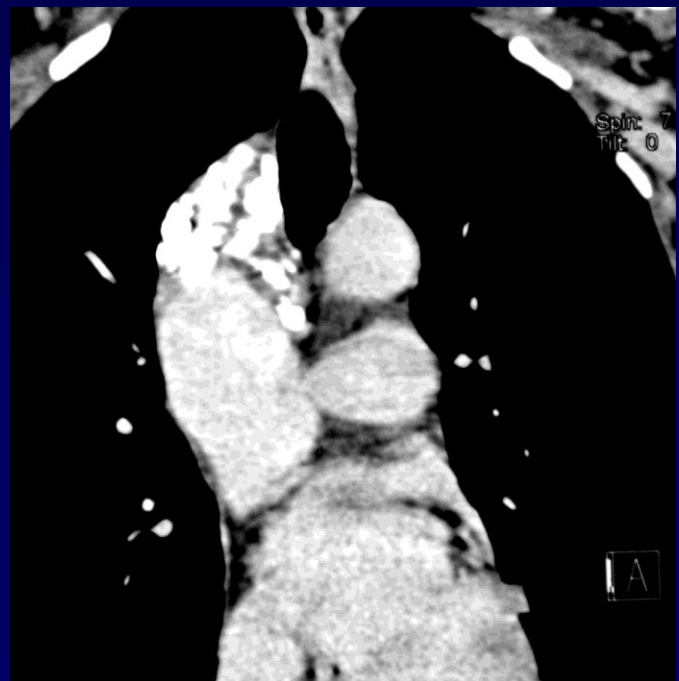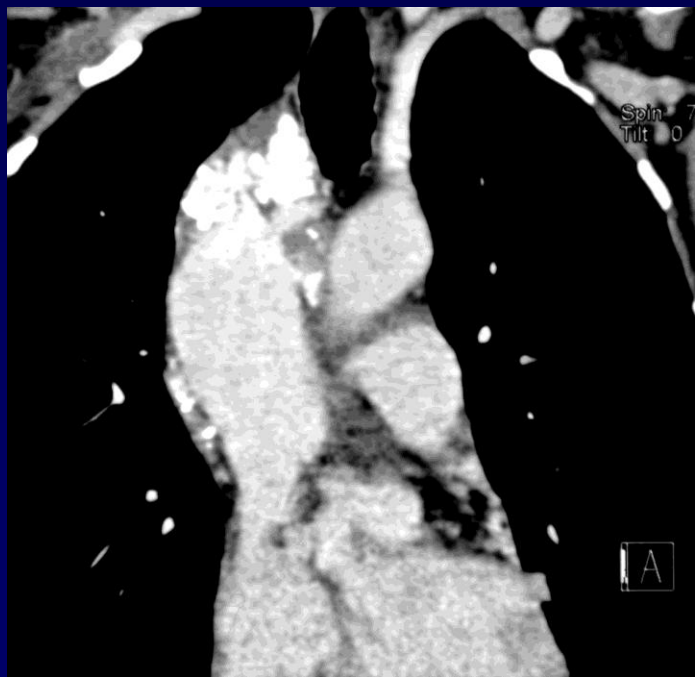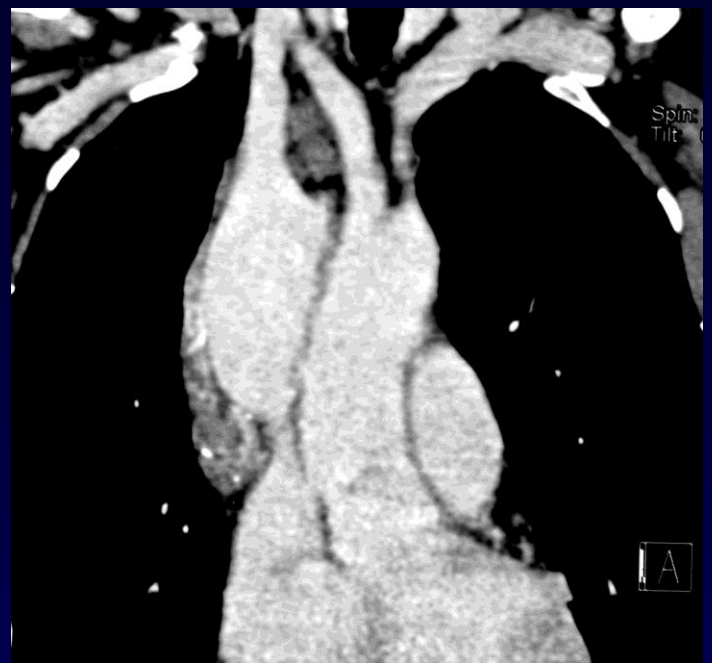


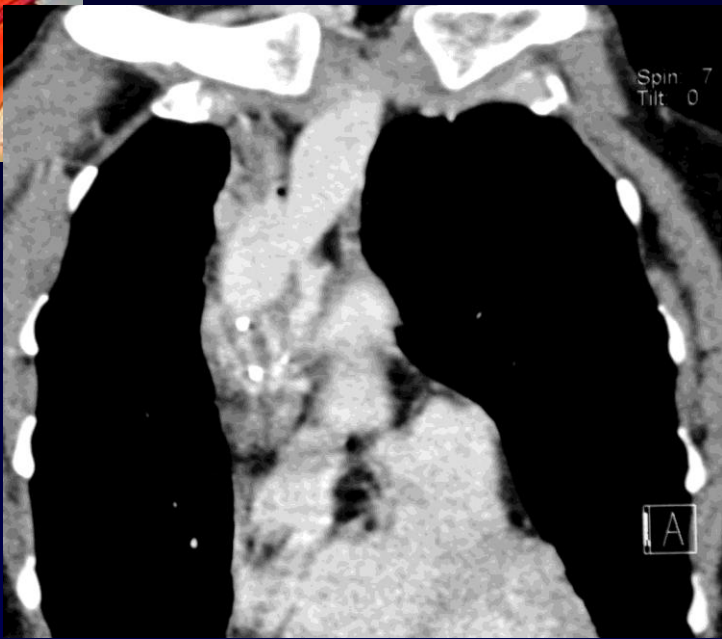
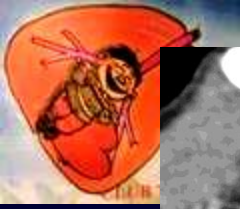
**Sans injection de produit
de contraste**

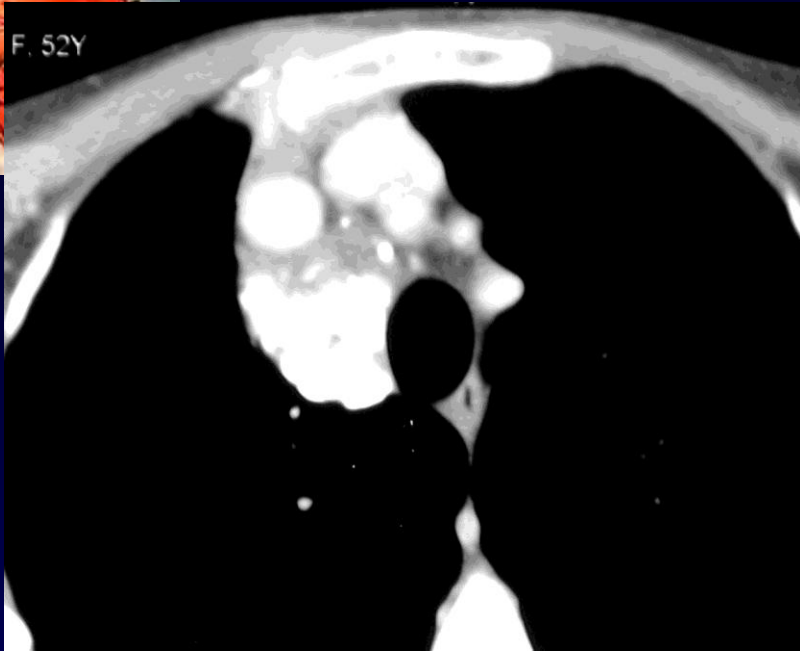

**Sans injection de produit
de contraste**

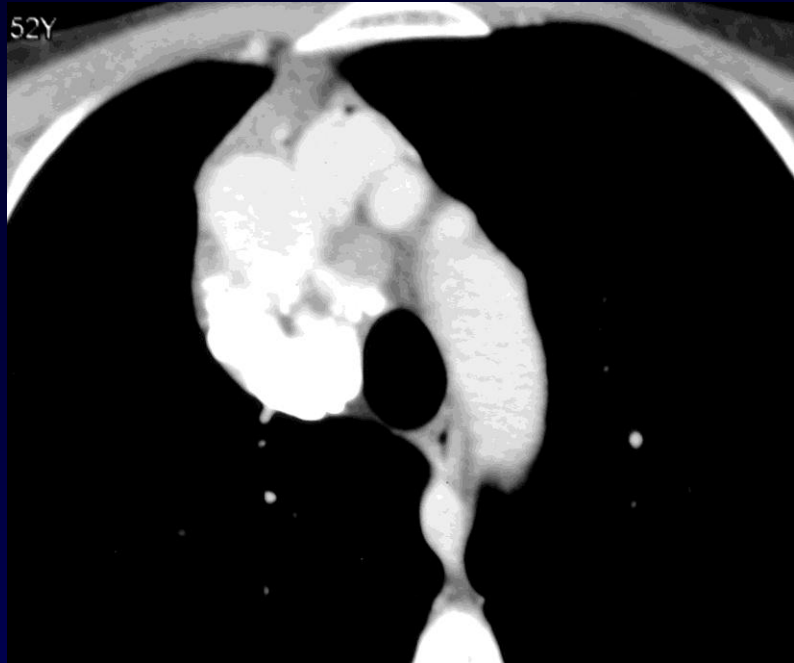




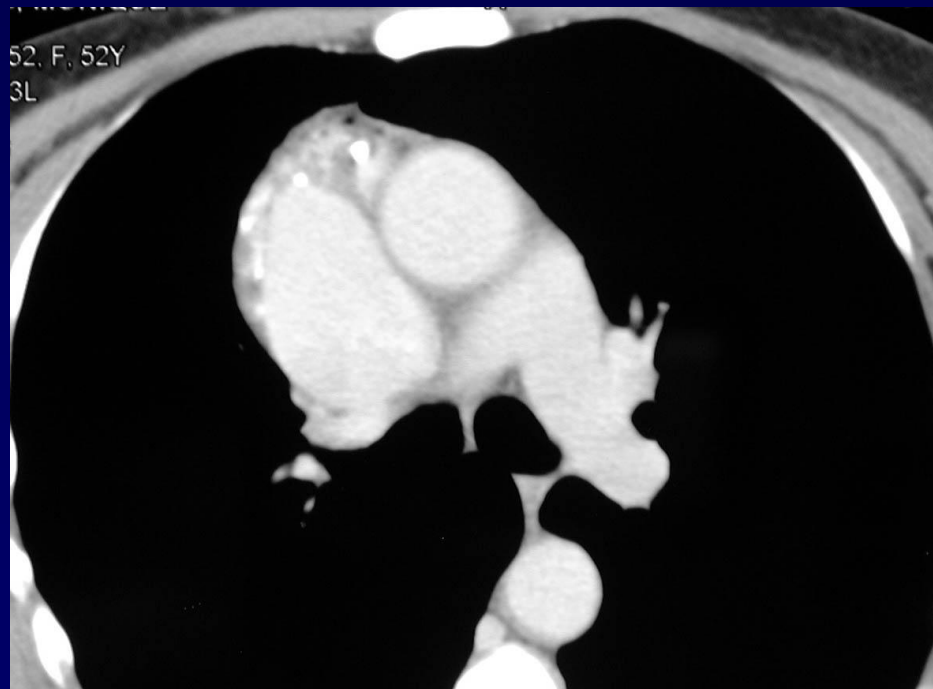F. 52Y

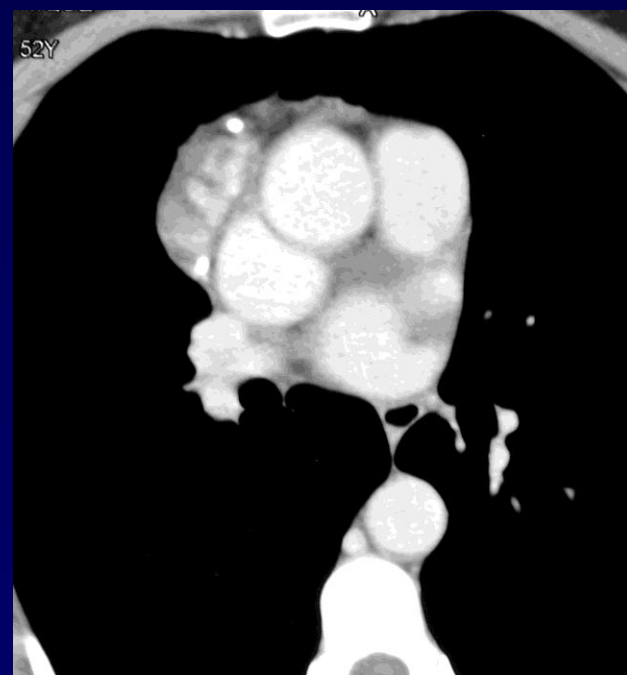
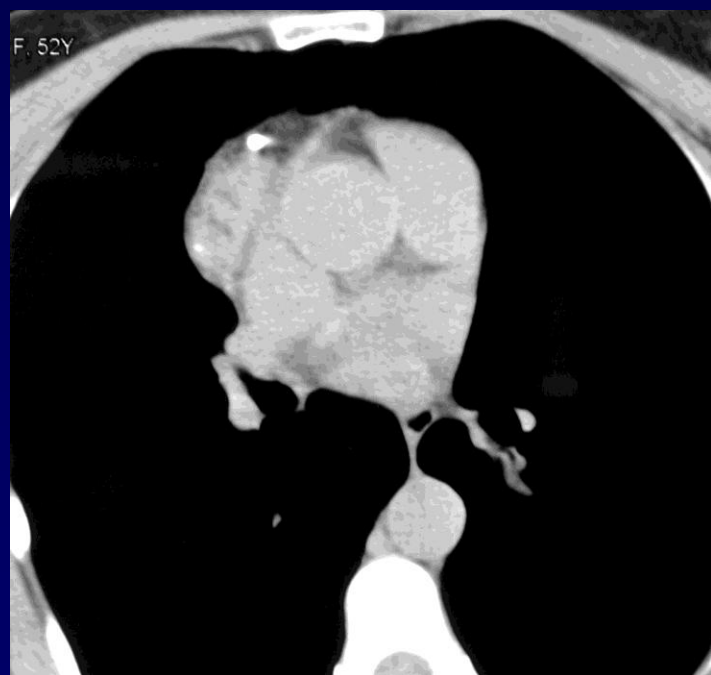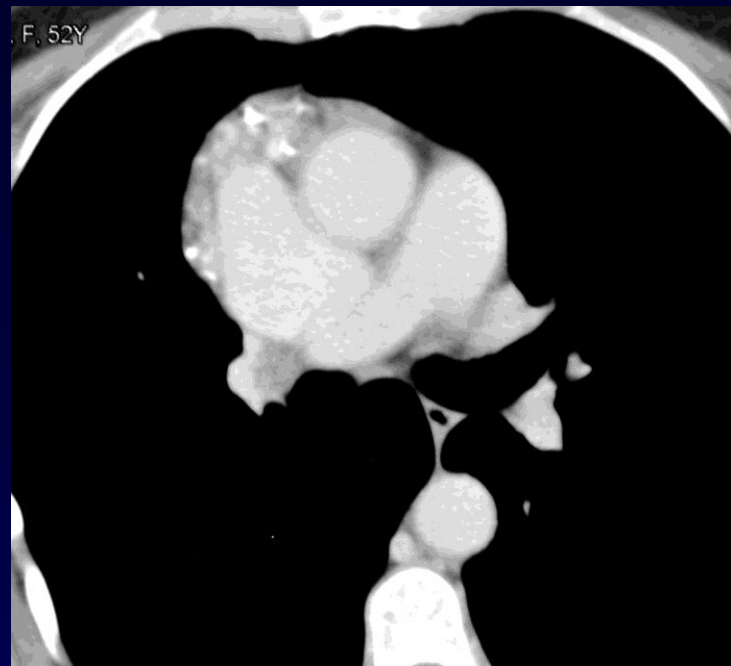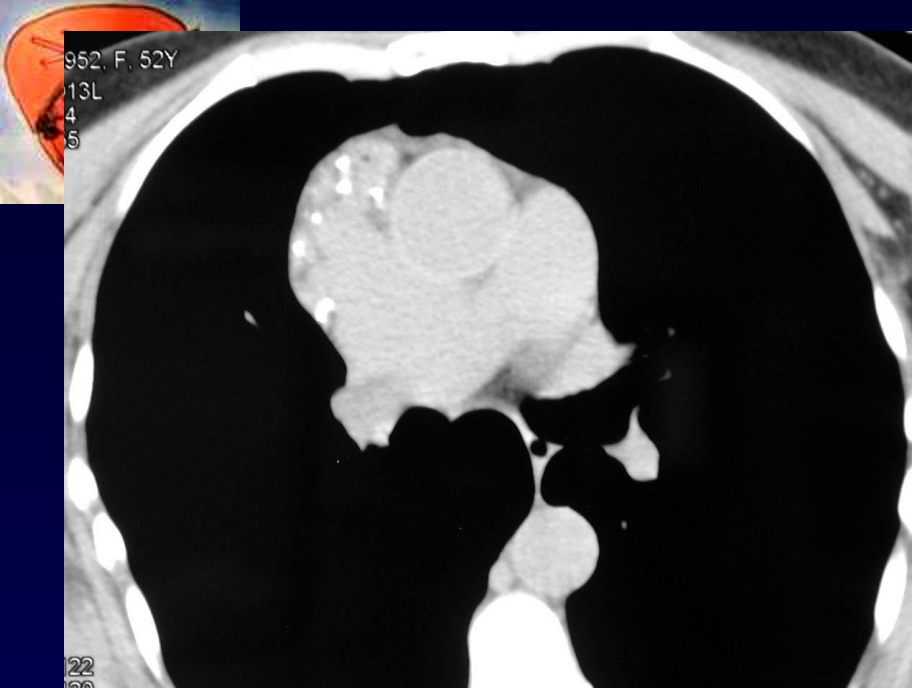


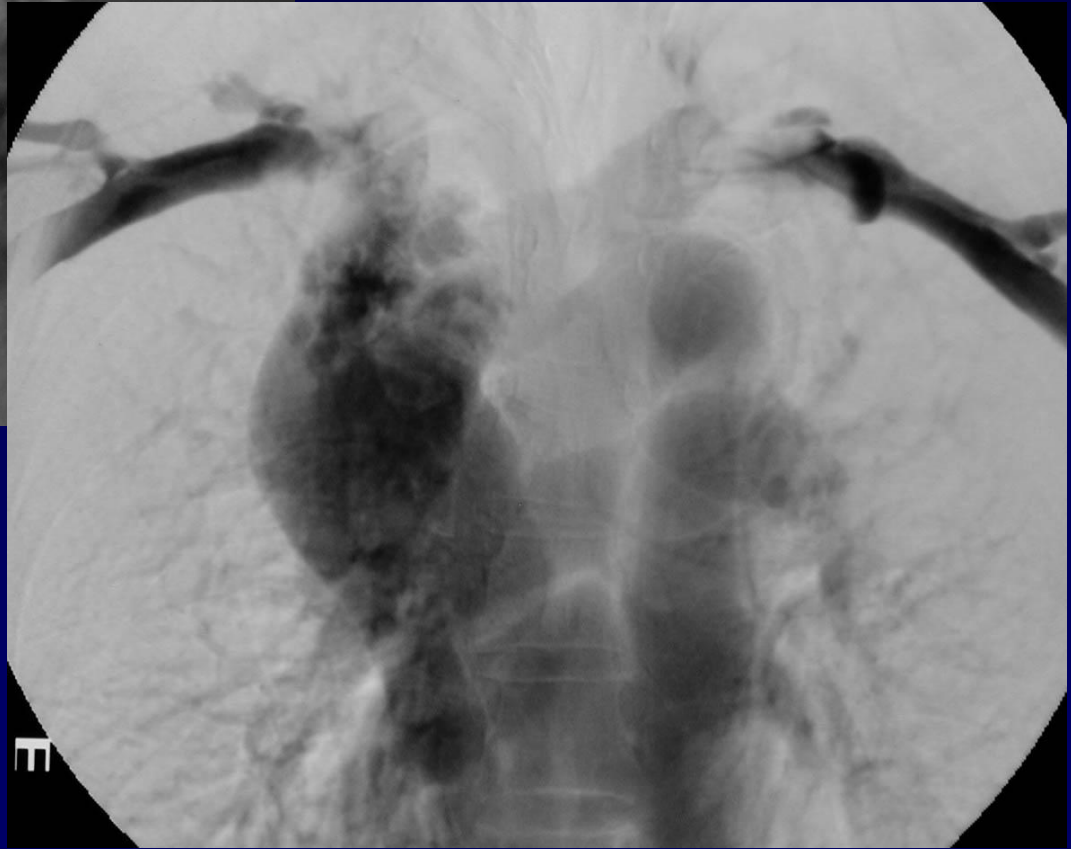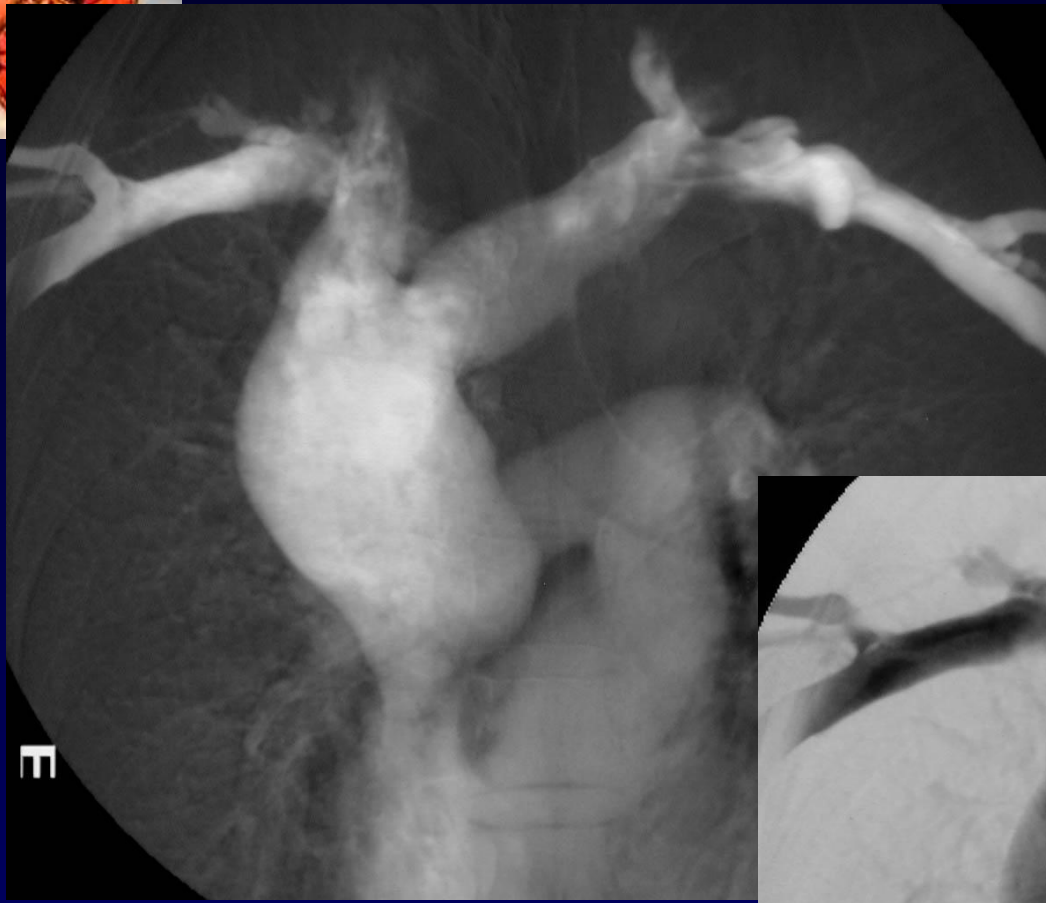52Y

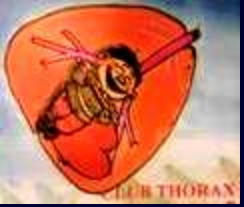

52, F, 52Y
3L









Diagnostic ?



Angiome médiastinal

ET

**Ectasie de la veine cave
supérieure**